

Automatic assessment of intrabdominal fat by MRI

Peter Stanley Jørgensen¹, Rasmus Larsen¹, and Kristian Wraae²

¹ Informatics and Mathematical Modelling, Technical University of Denmark, Lyngby, Denmark

² Odense University Hospital, Odense, Denmark

There is growing evidence that obesity is related to a number of metabolic disturbances such as diabetes and cardiovascular disease [1]. It is of scientific importance to be able to accurately measure both visceral adipose tissue (VAT) and subcutaneous adipose tissue (SAT) distributions in the abdomen. The development of a robust and accurate method for unsupervised segmentation of visceral and subcutaneous adipose tissue would be a both inexpensive and fast way of assessing abdominal fat.

Data was acquired from 300 patients consisting of MRI volume scans in an anatomically bounded unit, ranging from the bottom of the second lumbar vertebrae to the bottom the 5th lumbar vertebrae.

The slowly varying bias field present on all the MRI volumes was corrected using a new way of sampling same tissue voxels evenly distributed over the subjects anatomy. The bias field was estimated by fitting a 3D thin plate spline to the sampled same tissue voxels.

Automatic outlining of 3 image structures was necessary in order to determine the desired fat distributions: The external SAT outline, the internal SAT outline and the VAT area outline (See Figure 1(b)). First, a rough identification of the location of each outline was found using an active shape model [2] (ASM) trained on a small sample of slices. Outlines found using this rough model were then used as a constraint to drive a simple dynamic programming (DP) through polar transformed images. Fuzzy c-mean clustering was used to segment adipose tissue from other tissue inside the VAT area.

A total of 14 subject volumes were randomly selected and segmented both automatic and manually. The correlation between the unsupervised and manual segmentation was high for both VAT ($r = 0.9599$, $P < 0.0001$) and SAT ($r = 0.9917$, $P < 0.0001$).

The combination of ASM with DP makes the method both robust and accurate by combining the robust but inaccurate high level ASM method with the more fragile but accurate low level DP method. The method proposed here is fully automated and has a very low amount of adjustable parameters. The low amount of parameters makes the method easily adaptable to new data, such as images acquired from other scanners.

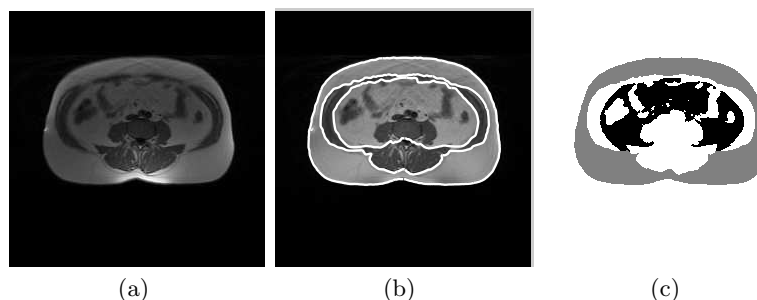


Fig. 1. An example slice. (a) The original biased slice. (b) The outlines of the inner and outer SAT borders and the VAT border superimposed on the bias corrected image. (c) The final segmentation into SAT (grey), VAT (grey) and other tissue (white).

References

1. Vague, J.: The degree of masculine differentiation of obesity: a factor determining predisposition to diabetes, atherosclerosis, gout, and uric calculous disease. In: *Obes Res.* Volume 4. (1996)
2. Cootes, T.F., Taylor, C.J.: Statistical models of appearance for medical image analysis and computer vision. appears in *Proc. SPIE Medical Imaging* (2001)